

THE JOURNAL OF
Egyptian
Archaeology

VOLUME 66
1980

PUBLISHED BY
THE EGYPT EXPLORATION SOCIETY
3 DOUGHTY MEWS, LONDON WC1N 2PG

Price to non-members £10.00

ISSN 0307-5133

THE JOURNAL OF
Egyptian Archaeology

VOLUME 66

PUBLISHED BY
THE EGYPT EXPLORATION SOCIETY
3 DOUGHTY MEWS, LONDON WC1N 2PG
1980

CONTENTS

	PAGE
EDITORIAL FOREWORD	I
PRELIMINARY REPORT ON THE EL-'AMARNA EXPEDITION, 1979	Barry J. Kemp 5
THE 'ANUBIEION', NORTH SAQQÂRA, PRELIMINARY REPORT, 1978-1979	H. S. Smith and D. G. Jeffreys 17
NORTH SAQQÂRA 1978-1979: THE COPTIC CEMETERY SITE AT THE SACRED ANIMAL NECROPOLIS, PRELIMINARY REPORT	D. G. Jeffreys and E. Strouhal 28
OBSERVATIONS ON A COLLECTION OF CRANIA FROM THE MASTABAS OF THE REIGN OF CHEOPS AT GÎZA	F. Filce Leek 36
EXCAVATIONS AT THE PYRAMID OF USERKAF 1979: PRE- LIMINARY REPORT	'Ali el-Khouli. 46
A MEMPHITE TRIAD	L. Kákosy 48
THE UPPER COURT COLONNADE OF HATSHEPSUT'S TEMPLE AT DEIR EL-BAĦRI	Z. Wysocki 54
TWO LUTE-PLAYERS OF THE AMARNA ERA	Kate Bosse-Griffiths 70
HISTORICAL OBSERVATIONS ON THE MILITARY RELIEFS OF ABU SIMBEL AND OTHER RAMESSIDE TEMPLES IN NUBIA	Anthony J. Spalinger 83
TERMS OF RELATIONSHIP AT DEIR EL-MEDÎNA	M. L. Bierbrier 100
AN ACCOUNTS PAPYRUS FROM THEBES	C. J. Eyre 108
A SALE OF INHERITED PROPERTY FROM THE REIGN OF DARIUS I	Eugene Cruz-Uribe. 120
ADAPTATION OF ANCIENT EGYPTIAN TEXTS TO THE TEMPLE RITUAL AT PHILAE	L. W. Žabkar 127
EGYPTIAN ANTIQUITIES ACQUIRED IN 1978 BY MUSEUMS IN THE UNITED KINGDOM	Janine Bourriau 137
RESHEPH IN EGYPT	Raphael Giveon 144

BRIEF COMMUNICATIONS: A sacrificial bull's head from Illahun, *by* Richard Burleigh and Juliet Clutton-Brock, p. 151; 'Liaison' *n* reconsidered, *by* M. A. Nur-el-Din, p. 153; Observations on recent discoveries at Wâdî Gawâsîs, *by* Abdel Monem A. H. Sayed, p. 154; An important lacuna in Ranke's *Personennamen*: the Tomb of *Rnni*, *by* H. G. Fischer, p. 157; Lexikalisches zum Papyrus Berlin 10463, *by* M. Görg, p. 160; *Sbht* as a term for a wooden screen, *by* Patricia Spencer, p. 161; Amenophis III and Akhenaten: co-regency proved? *by* Juliette Bentley, p. 164; Reconstruction of a shoulder harp in the British Museum, *by* Bo Lawergren, p. 165; Chicago, Or. Inst. 8798, 3-4 and Cairo CG 34057, 12-13 (*JEA* 62, 59, 61-2, pls. XI, XIA), *by* Jaromír Málek, p. 168; The reign-length of Ramesses VII, *by* C. J. Eyre, p. 168; Harmachis the High Priest of Memphis: Wilkinson's copy of BM 391, *by* J. D. Ray, p. 170; An illustration of the Coffin Texts on a Roman cartonnage, *by* K. Myśliwiec, p. 171; A Second Dynasty king in a Demotic Papyrus of the Roman Period, *by* M. Smith, p. 173; Current research for higher degrees in Egyptology, Coptic, and related studies in the United Kingdom, No. 4, *by* G. T. Martin, p. 174.

REVIEWS	PAGE
JANET H. JOHNSON and EDWARD F. WENTE, Eds., <i>Studies in Honor of George R. Hughes</i>	Reviewed by M. L. Bierbrier 176
JAN ASSMANN, ERIKA FEUCHT, and REINHARD GRIESHAMMER, Eds., <i>Fragen an die altägyptische Literatur. Studien zum Gedenken an Eberhard Otto</i>	J. Gwyn Griffiths 178

	PAGE
BERTHA PORTER and ROSALIND L. B. MOSS, assisted by ETHEL W. BURNEY, <i>Topographical Bibliography of Ancient Egyptian Hieroglyphic Texts, Reliefs and Paintings</i> . II. Theban Temples. Second Edition, revised and augmented. III. Memphis. Part 2. Saqqâra to Dahshûr. Second Edition, revised and augmented by JAROMÍR MÁLEK	T. G. H. James 179
JÜRGEN OSING, <i>Der spätägyptische Papyrus BM 10808</i>	A. Shisha-Halevy 181
M. A. A. NUR-EL-DIN, <i>The Demotic Ostraca in the National Museum of Antiquities at Leiden</i>	W. J. Tait 186
PIERRE DU BOURGUET, <i>Grammaire fonctionnelle et pro- gressive de l'égyptien démotique</i>	Carol A. R. Andrews 188
HERWIG MAEHLER, <i>Papyri aus Hermupolis. Ägyptische Urkunden aus den Staatlichen Museen Berlin, Griechische Urkunden, XII</i>	J. David Thomas 189
W. M. BRASHEAR, <i>Greek Papyri from Roman Egypt. Ägyptische Urkunden aus den Staatlichen Museen Berlin, Griechische Urkunden, XIII</i>	Alan K. Bowman 190

LIST OF PLATES

(at end)

PLATES I–II	El-'Amarna Survey, 1979
PLATE III	The 'Anubieion', North Saqqâra, 1978–9
PLATES IV–V	Crania from the Mastabas of the Reign of Cheops at Gîza
PLATE VI	Excavations at the Pyramid of Userkaf
PLATE VII	A Memphite Triad
PLATES VIII–IX	The Upper Court Colonnade of Ḥatshepsut's Temple at Deir el-Baḥri
PLATES X–XI	Two Lute-Players of the Amarna Age
PLATES XII–XIII	An Accounts Papyrus from Thebes
PLATE XIV	A Sale of Inherited Property from the Reign of Darius I
PLATES XV–XVI	Adaptation of Ancient Egyptian Texts to the Temple Ritual at Philae
PLATES XVII–XVIII	Museum Acquisitions, 1978
PLATES XIX–XX	Resheph in Egypt
PLATE XXI	A Sacrificial Bull's Head from Illahun
PLATES XXI–XXII	Discoveries at Wâdî Gawâsis
PLATE XXIII	Reconstruction of a Shoulder Harp in the British Museum
PLATE XXIV	An Illustration to the Coffin Texts

OBSERVATIONS ON A COLLECTION OF CRANIA FROM THE MASTABAS OF THE REIGN OF CHEOPS AT GÎZA

By F. FILCE LEEK

SYSTEMATIC excavation of the Western Cemetery of Cheops' pyramid was begun in 1902 by three expeditions, one of which was fielded by the University of Leipzig, represented by Professor Georg Steindorff (Sieglin Expedition), and later transferred to the Akademie der Wissenschaften of Vienna and the Roemer-Pelizaeus Museum, Hildesheim, Germany, represented by Professor Hermann Junker. The area was divided into three east-west strips and the middle one was allotted to the Sieglin Expedition. Below are listed those excavated by Junker in 1911/12 and 1912/13 together with the corresponding numbers of Reisner:

	<i>Junker</i> ¹				<i>Reisner</i> ²		
VIIISS	VIIIS	VIIIN	VIIINN	4840	4850	4860	2155
	VIIS	VIIN	VIINN		4750	4760	3135
	VIS	VIN			4650	4660	
	VS	VN			4550	4560	
	IVS	IVN			4450	4460	
	IIIS	IIIN			4350	4360	
	IIS	IIN			4250	4260	
	IS	IN			4150	4160	

During his first two seasons, Junker recovered many human remains and of these 177 dry skulls are held in the Naturhistorisches Museum, Vienna. It is this collection that forms the basis of the present study. That there are more skulls in the collection than there were mastabas excavated is due to the fact that, in many, there were several shafts or pits with a burial in each. When it was found that a number had been given to each skull, it was hoped to be able to equate each with its mastaba. This unfortunately proved impossible because the numeral given to an individual skull in no way complied with that of the mastaba. Every help was give by Dr H. Satzinger, Aegyptisch-Orientalische Sammlung, Kunsthistorisches Museum, Vienna, to work out a correlation, but the efforts were successful in such a limited number that the idea was abandoned.

I should like to thank Dr Johann Szilvássy, Anthropologische Abteilung, Naturhistorisches Museum, and Dr Helmut G. Satzinger, Aegyptisch-Orientalische Sammlung, Kunsthistorisches Museum, Vienna, for their active and constant co-operation, which was greater than could be expected by a visiting colleague. My wife afforded considerable help during the investigation and I am indeed grateful. I wish also to thank Dr D. M. Dixon who read the MS and made interesting suggestions which have been incorporated into the text.

¹ See H. Junker, *Giza*, 1 (Vienna, 1913), 2, 81.

² See G. A. Reisner, *History of the Giza Necropolis*, 1 (Cambridge, 1942), maps no. 2.

The condition of the skulls varied greatly; some were in fragments, others were amazingly well preserved. The remains of one resembled pieces of Roman tesserae before being made into a mosaic, whilst another was without a bone fractured, even retaining its very vulnerable styloid processes. Valuable information, however, could be gained even from the most fragmented skull. For example, amongst a collection of apparently useless pieces was the head of a mandible, which showed marked arthritic changes, whilst another was a part of an orbit which exhibited cribra orbitalia. One of the best-preserved skulls revealed what was probably the most significant fact to emerge from the investigation, namely, that an entrance had been made into the cranial vault via the cribriform plate of the ethmoid bone. This confirms the view that the removal of the brain by this method was practised by some embalmers as early as the Fourth Dynasty (c. 2650 BC).

It is unfortunate that, in a proportion of the specimens, the skulls were so fragmented that accurate determination of age and sex was impossible. This is also true in a number of instances where the morphological details were insufficient to give a clear indication of sex. However, it was possible to make interesting comparisons and deductions when the ages were expressed in decades and when the divisions of the sexes were increased to three, the third designated 'Ambiguous'.

Table showing age and sex of the 177 skulls³

<i>Age</i>	<i>Male</i>	<i>Female</i>	<i>Ambiguous</i>
0-9			6
10-19			3
20-29	10	22	1
30-39	37	18	2
40+	17	10	1
Ambiguous	15	8	27
Total	79	58	40

List of abnormalities

Genetically determined: metopic suture, mid-line depression of the skull, supraorbital notches and foramina, Wormian bones.

Unknown aetiology: parietal thinning.

Pathological defects: circumscribed osteoporosis on outer table of cranium, cribra orbitalia, osteoarthritis of mandibular condyle.

Dental defects: caries, attrition, alveolar abscesses and cysts, antral fistula, impacted lower third molars, congenital absence of wisdom teeth, alveolar bone disease.

Post-mortem interference: entrance into cranial vault.

Genetically determined abnormalities

Metopic suture. This condition arises from the persistence of the medial-frontal suture, which usually unites by the age of two years. It was observed on six occasions (see pl. IV, 1).

³ Since this table was compiled, the author discovered from the Museum's register that it is in complete accord with that made by Professor Josef Szombathy when the skulls entered the Naturhistorisches Museum.

F. FILCE LEEK

<i>Age</i>	<i>Male</i>	<i>Female</i>	<i>Ambiguous</i>
20-29	1	1	1
30-39	3		
Total	4	1	1

Mid-line depression of the skull. The sagittal suture usually runs along the vortex of the skull but in a number of instances this suture ran along a shallow saucer-shaped depression. This is almost certainly a variation of the shape of the vault. As it was well represented in the lower age-groups, it cannot be regarded as part of the ageing process.

<i>Age</i>	<i>Male</i>	<i>Female</i>	<i>Juvenile</i>	<i>Ambiguous</i>
10-19			1	
20-29		1		2
30-39		3		
40+	5			
Total	5	4	1	2

Supraorbital notches and foramina. The supraorbital vessels pass through a notch or a foramen in the superior orbital margin at the junction of its middle and inner third (see pl. IV, 2). This varies from a scarcely perceptible break in the line of the margin to a deep invagination on one or more foramina. The following are the pathways observed: right and left notches, 53; right and left foramen, 17; right notch and left foramen, 10; right foramen and left notch, 13.

Wormian bones. These are extra-sutural bones, varying in size and complexity, occurring along the lamdoid suture.

	<i>Male</i>	<i>Female</i>	<i>Juvenile</i>
Bilateral		6	
Unilateral	5	4	1

There is every reason to believe that all the above variations are inherited as dominant traits. Had more been known about the relationship of the individuals in each tomb, any of these characteristics could have been used as supporting evidence of family relationships.

Abnormality of unknown aetiology

Parietal thinning. This is an oblong depressed thinning of the outer plate of the posterior part of the parietal bone and usually appears on both sides of the head (see pl. IV, 3). Elliot Smith's anatomical investigations of Ancient Egyptian human remains led him to the conclusion that the condition was confined to the upper classes and was seen amongst those living between the Second and Twentieth Dynasties. Because it is

a non-inflammatory condition, he postulated that it was the result of wearing heavy wigs,⁴ a fashion known to be common during certain periods because of their representation on tomb paintings and other art forms. This hypothesis is no longer accepted because the condition has been found amongst other populations who, as far as is known, did not wear wigs, and also amongst age-groups other than those postulated by Elliot Smith. The author thinks that the wearing of wigs could not possibly produce such localized anomalies because their weight would be borne by the whole of the dome of the head, and so could not be responsible for such limited areas of pressure, although the condition is so frequently found in a symmetrical pattern. He thinks that, whilst the condition is sometimes the result of an ageing process, it could also have been genetically controlled, because observation of the shapes of the heads of different age groups of bald men reveals varying patterns, some of which could be the result of an underlying parietal thinning.

<i>Age</i>	<i>Male</i>	<i>Female</i>	<i>Ambiguous</i>
30-39		2	
40+	6+1 unilateral	1+1 slight	2+1 slight
Ambiguous		1	

Pathological abnormalities

Osteoporosis of the outer table of the cranium. Almost all examples of this condition consisted of circumscribed areas of loss of the cortical layer of bone exposing the diploe or cancellous bone beneath, but there were other examples showing a more diffuse area. The parietal bones were most commonly affected (see pl. IV, 4). The cause of this condition has been variously described in palaeopathological writings, and in one of these it is suggested that it is the result of carrying heavy burdens on the head, while yet another has blamed an iron-deficiency anaemia.⁵ To add to the number of hypotheses as to the cause of this abnormality, I would suggest that it is due, in the first instance, to a primary infection of the scalp, followed by a secondary infection of the bone. Lucas⁶ reports that locks of artificial hair were worn as early as the First Dynasty and indeed many wigs have been recovered from tombs of later periods. The need for this fashion could well have arisen not only from loss of hair due to ageing, but from localized loss of hair due to the infection of the scalp by bacteria or fungi. Life on the desert and at some distance from available water must at times have made attention to hygiene difficult and surely this could be a contributing factor to any disease of the scalp.

Cribra orbitalia. This condition is similar in appearance to the effect of osteoporosis of the cranium in that there is an exposure of the trabeculae of the cancellous bone, giving a sieve-like appearance to the upper part of the orbit. One suggestion is that it

⁴ See Elliot Smith, 'The causation of the symmetrical thinning on the parietal bone', *J. Anat. Phys.* 41, 232-3.

⁵ See J. L. Angel, 'Porotic hyperostosis or osteoporosis symmetrica', in D. Brothwell and A. T. Sandison (eds.), *Diseases in Antiquity* (Illinois, 1967), 378-89.

⁶ See A. Lucas, rev. J. R. Harris, *Ancient Egyptian Materials and Industries*, 4th edn. (London, 1962), 30-2.

arises from pressures resulting from an enlarged lacrimal gland and yet another explanation is that it is caused by thalassaemia or sickle-cell anaemia.⁷ Many modern workers consider that cribra orbitalia and osteoporosis of the cranium both arise from the same cause. My own view is different, and is based on the fact that there were seven instances of osteoporosis of the cranium and ten instances of cribra orbitalia to be seen in the 177 skulls and yet in no one instance did both conditions occur in the same individual, which might well have been expected if both originated from the same cause. Anyone walking in the streets of small towns and villages in Egypt will observe the complete indifference shown by young children and adults to clusters of flies in and around their eyes and that many of them suffer from inflammation of the eyes and associated structures. This could have been the same in ancient times when inflammation of the eyes could have been the cause of cribra orbitalia. An even more probable initiating factor may have been the inflammation set up by irritation of wind-blown desert sand. There is no reason to believe that sand storms were less frequent in ancient times than now, and the damaging effects of these are difficult to avoid.

Osteoarthritis of the mandibular condyle. Because of post-mortem damage to many mandibles a complete record of the pathological changes was impossible, but the following were observed: erosion of the superior surface; progressive and regressive remodeling of the superior surface; an anterior ridge; saucer-shaped depression on the posterior surface; saucer-shaped depression on the posterior surface and erosion; massive bony additions including mushroom-shaped condyle; osteophytes. Abnormalities were frequently seen on both condyles but rarely of a similar nature. The number of individuals affected must have been considerably greater than is indicated in the following list because the head of the mandibular condyle is particularly prone to post-mortem damage.

<i>Age</i>	<i>Males</i>	<i>Females</i>	<i>Ambiguous</i>
10-19			1
20-29	9	9	
30-39	23	6	
40+	16	7	
Ambiguous			11
Total	48	22	12

Changes in the head of the mandibular condyle are brought about under modern conditions by (a) abnormalities in the articular cartilage and the synovial membrane; (b) ageing; (c) overload of the functional capacity of the joint. Present-day surveys

⁷ See S. Hillson, *Chronic Anaemias in the Nile Valley* (in press). For a general discussion on disease in earlier times see Brothwell and Sandison, *op. cit.*, and for Egypt in particular see O. V. Nielsen, *Human Remains* (Copenhagen, 1970).

show that disturbances are seen more frequently in women than in men. This is because women appear to be more susceptible to both rheumatoid and osteoarthritis.⁸

By this survey the author had hoped to discover, on the one hand, what proportion of changes seen on the head of the condyle were the result of these two diseases, and, on the other, how many cases were the result of an overload of the functional capacity of the temporo-mandibular joint. This latter condition would be brought about by the abnormal muscular movements induced by the changes in the cuspal design of the teeth caused by attrition. Because all the changes in the mandibular condyle were associated with marked changes in the cuspal design due to attrition, the conclusion reached was that rheumatoid arthritis played no part but that all the changes in the joint were due to an overload of its functional capacity.

Dental defects

Caries. The exact number of carious cavities in the teeth of these nobles will never be known because many have fallen from their sockets post mortem, but thirty-three cavities were found in twenty-two dentitions (see pl. V, 4). These cavities appear in all age-groups, and yet only one had progressed to the pulp chamber and had caused an apical abscess. All the other cavities were small and contained. The conclusion reached was that these people had caries-resistant teeth and, although the disease was found in some 12 per cent, as there were so many incomplete dentitions it is possible that the true proportion was around 15 per cent. The following list of dentitions revealing dental caries shows that male and female were equally affected:

<i>Age</i>	<i>Male</i>	<i>Female</i>	<i>Ambiguous</i>
10-19			1
20-29	5	3	
30-39	2	5	
40+		1	
Ambiguous	2	2	1
Total	9	11	2

Attrition. The degree of attrition seen on the occlusal surfaces of individual teeth in a dentition varies considerably and there is usually greater evidence to be found on the buccal teeth than on the incisors. In examples of dentitions with a normal occlusal pattern the greatest wear is on the first permanent molar and it decreases on the other molar teeth in a direct proportion to the length of time of their eruption. So marked and constant is this difference that it can be used as an indication of age well into the adult period. It might be thought that the wear would reduce the occlusal surface in a regular and horizontal plane, but this is rarely so. In some few instances, the wear results in a saucer-shaped depression on the occlusal surface but is mostly in the nature

⁸ See P. A. Toller, 'Osteoarthrosis of the mandibular condyle', *Brit. Dent. J.* 134, 6 (1973), 223-31, and H. Ogus, 'Rheumatoid arthritis of the temporomandibular joint', *Brit. J. Oral Surg.* 12 (1975), 275-84.

of an inclined plane in which the mandibular molars show the plane descending more deeply to the cheek side, whilst, in the maxillary molars, the plane descends to the palatal side. Attrition on the teeth begins at an early age and in this, and every other collection the author has examined, the condition is to be seen on all juvenile dentitions (i.e. 6+ years). Examinations of dentitions in collections of medieval and earlier populations always reveal attrition, but it is never so widespread or as severe as to be seen on those from Ancient Egypt. The reason for this is fully discussed in *JEA* 58, 126-32.

In this survey the following attrition-index was employed using the first permanent molar as the guide: flattening of enamel cusps, 1; exposure of dentine, 2; exposure of secondary dentine, 3; exposure of pulp chamber, 4; progressive destruction of crown, 5. Every dentition with retained molar teeth showed attrition and as the age progressed so did the degree of attrition. By using the results as a basis for further calculation it was found that males showed an approximately 37 per cent greater degree of attrition than females. This is a reflection of the difference in power of the muscles of mastication.

Dental abscesses and cysts. All the sixty-four apical abscesses were, with one solitary exception, the result of necrosis of the dental pulp caused by attrition (see pl. V, 2). As might be expected, the number of males so affected was more than twice that of females, since their muscles of mastication were so much stronger. As it was not possible to X-ray the dentitions, only those abscesses that had destroyed the outer or inner alveolar plate were recognized. There would also be an unknown number of chronic abscesses and abscesses that had escaped into the maxillary antrum that passed undetected. Dental cysts were recognized by their smooth walls and were seen in three instances.

<i>Age</i>	<i>Male</i>	<i>Female</i>	<i>Ambiguous</i>
20-29	3 (5)	3 (3)	
30-39	14 (22)	4 (3)	2 (2)
40+	10 (19)	5 (6)	3 (3)

Note. The figure in brackets () denotes the total number of abscesses.

Antral fistula. A small number of crania was fragmented in such a manner that the inner part of the maxillary antrum was revealed. The size, shape, and convolutions of each base varied. In three cases there was a fistula opening into the base arising from an apical infection of the first permanent molar (see pl. V, 3). In two instances the orifice was a clean-cut circle 3 mm in diameter, whilst in the third example a considerable osseous reaction to the infection had taken place, and around the still clean-cut orifice was a mass of bony tissue 3 mm high. It is idle to speculate on the number of infected antra in the collection because there is no non-destructive examination that could possibly give the true answer, but, as an apical infection of the upper molar teeth was a common affliction, an infected maxillary sinus must have been suffered by a number of individuals. In instances of upper molar teeth where there is an obvious

exposure of the pulp chamber, and no destruction of the surrounding alveolar bone, it is almost certain that the pus escaped into the antrum.

Impacted lower third molars. Two mandibles showed mesially impacted lower third molar teeth, one in a juvenile skull and the other in an adult male (see pl. V, 1). Since the surrounding bone displayed no signs of an inflammatory reaction, neither would have given rise to any symptoms. In another mandible, however, the bone around a fully erupted wisdom tooth showed the effects of a severe infection of the surrounding soft tissues, so much so, that during life these tissues would have been so badly inflamed and swollen that at times the lower jaw must have been immobilized.

Congenital absence of wisdom teeth. In modern times there are frequent examples of impacted, buried wisdom teeth and wisdom teeth that have failed to develop. It has always been assumed that these conditions arise from the lack of stimulation to the developing jaws by the muscles of mastication as the result of the habit of eating soft and non-fibrous foods. Except in three instances, where there was a crowding of the anterior teeth, all the jaws were well developed, so this explanation cannot apply in the case of the Ancient Egyptians. Unfortunately no explanation for this anomaly can be offered.

<i>Age</i>	<i>Male</i>	<i>Female</i>	<i>Ambiguous</i>
20-29	1 (1)	2 (2 and 4)	
30-39	1 (4)		
40+	2 (1 and 4)	1 (1)	1 (2)
Ambiguous	1 (1)	1 (1)	

Note. The figures within the brackets () denote the number of missing third molar teeth in each individual.

Alveolar bone disease. In modern times alveolar bone disease is preceded by an inflammation of the overlying soft tissues. The dental papillae become swollen and inflamed and finally they split, thus allowing a bacterial invasion of the alveolar bone beneath, and this is followed by the formation of bony craters. Thus the disease progresses from without inwards. This was also the pattern followed by the disease in ancient times, but there are to be seen many examples in this and other collections where the breakdown of the tooth's supporting structures cannot be explained by this pattern.

Normally the stresses and strains applied to the occlusal surface of a tooth by mastication are transferred vertically down the body of the tooth and are borne by the surrounding elastic fibres of the periodontal membrane and the alveolar bone. When the cuspal design is changed to an inclined plane by attrition, these stresses are transferred down the root in an oblique direction and the alveolar bone in the region of the tooth's apex is subject to very abnormal pressures, and after a time begins to break down. Examples are seen where the apex of a tooth has even been forced through its bony socket. Without doubt in some instances the two conditions prevailed at the same time. In this collection only one advanced case of alveolar bone disease was seen and that

in a male. In this instance the aetiology was different from the foregoing description. The alignment of the molar teeth encouraged retention of fibrous foods and, coupled with the lack of oral hygiene, would have aggravated the condition, causing advanced destruction of the alveolar bone, particularly of the interdental septum.

The following classification was used: + = pitting of the alveolar bone; ++ = absorption of the alveolar ridge; +++ = bifurcation of root exposed; ++++ = extensive destruction. The findings were as follows:

<i>Age</i>	<i>Male</i>	<i>Female</i>	<i>Ambiguous</i>
20-29	4+	4+	
30-39	3+ 1++	4+	
40+	4+ 7+++ 1++++	1+++	
Ambiguous	1+	1+	1++

Post-mortem operative interference

When the brain was removed during the process of embalming, access was usually made into the base of the skull via the nose. This was a relatively easy operation and if skilfully performed left little or no external signs of mutilation. Entrance into the cranial vault was made by means of a long, thin, pointed instrument passed up one side of the nostril to pierce the cribriform plate of the ethmoid bone. From examination of numerous dry skulls the author has come to the conclusion that the more skilful embalmer made just one small hole through the base of the skull, while the less competent made a large cavity by forcing an entrance up both sides of the nostril, at the same time destroying the nasal septum. Many skulls in this collection, however, showed no evidence of such interference. In a collection of undamaged skulls it is easy to classify those in which the brain had been removed by this method, but one often hesitates to make a decision when other bones have also suffered damage. Unfortunately many skulls in this collection had suffered post-mortem damage, but there was one which was completely intact with even the presence of its styloid processes, and quite obviously an entrance into the base of the skull had been made through the cribriform plate of the ethmoid bone. In at least three other examples it was possible to be assured that this operative procedure had also been followed. It can therefore be stated that, whilst the brain was not invariably removed during the process of embalming at this early period, such removal was certainly practised during the Fourth Dynasty, if only occasionally.

Conclusions

The human remains in this collection are of individuals who lived at a precise period in history, namely *c.* 2650 BC, and whose status in life was that of the highest in the land. It is regrettable that it is a small collection and, whilst it has certain uses for comparative purposes, its limitations in size must be recognized. It is possible that

a number of other anomalies could have been present in these skulls, but escaped detection because of post-mortem damage.

The genetically controlled abnormalities encountered cannot be used to prove relationships, but could be an aid when such are suspected. That bilateral parietal thinning was observed amongst these relatives and courtiers of the Pharaoh would contradict the belief that this was the result of carrying heavy weights on the head.

It is hoped that one day an acceptable explanation of osteoporosis of the skull and of cribra orbitalia will be forthcoming. Meanwhile there is confirmation that these conditions existed at this period, and that they do not have a common aetiology.

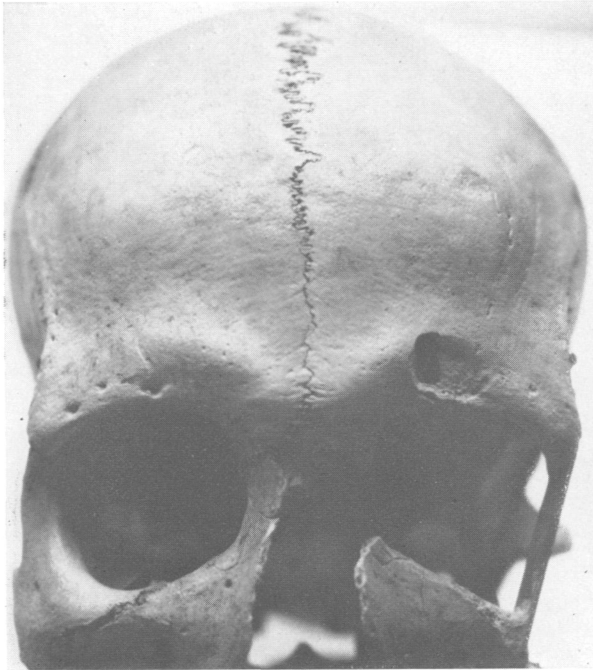
The pathological changes seen on the head of the mandibular condyle and the attrition on the cusps of the teeth do suggest that those of the highest social standing were accustomed to a diet no more free from contamination by mineral fragments than that of their less fortunate brethren.

There was a relative freedom from dental caries among these people, especially when their dental conditions are compared with those of individuals living towards the end of the dynastic period, but the destruction of the bone around the tooth's apex when necrosis of the dental pulp occurred was identical with that of other periods. We now know that impacted wisdom teeth occurred at this early period and, whilst in these particular instances they did not give rise to painful symptoms, this was only because an early death intervened.

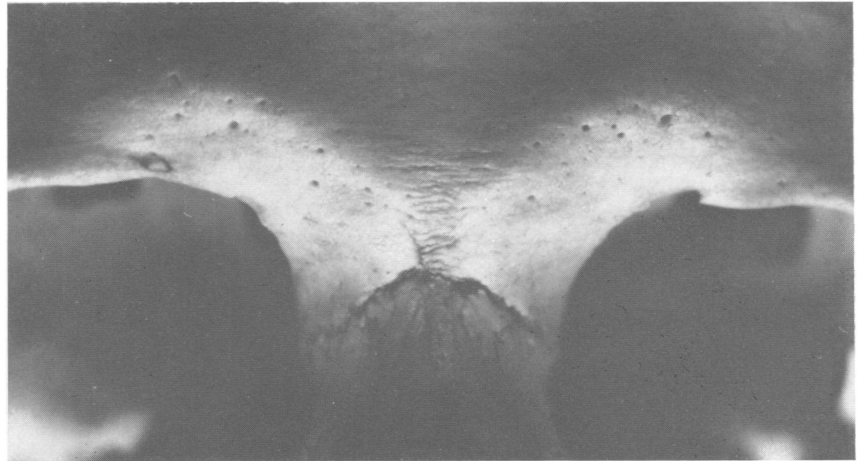
It is regrettable that so many skulls had suffered post-mortem damage, but several fragmented ones gave the opportunity to observe that 'sinus trouble' was a burden added to the daily life of some individuals.

No lack of continuity was to be seen in the base of many skulls but in one positively, and in three others almost certainly, an entrance had been forced through the cribriform plate of the ethmoid bone for the purposes of brain-removal during mummification, thus confirming that the practice existed during the Old Kingdom. No ante-mortem injuries were recognized nor were any benign or malignant neoplasms seen.

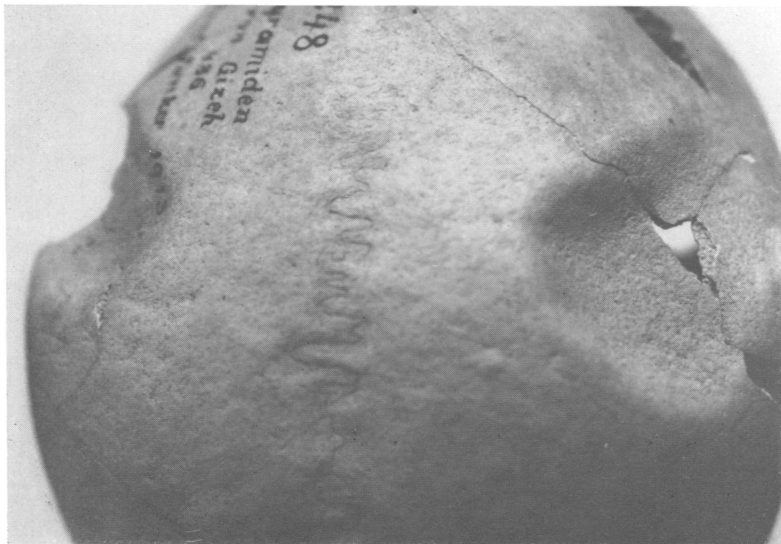
PLATE IV



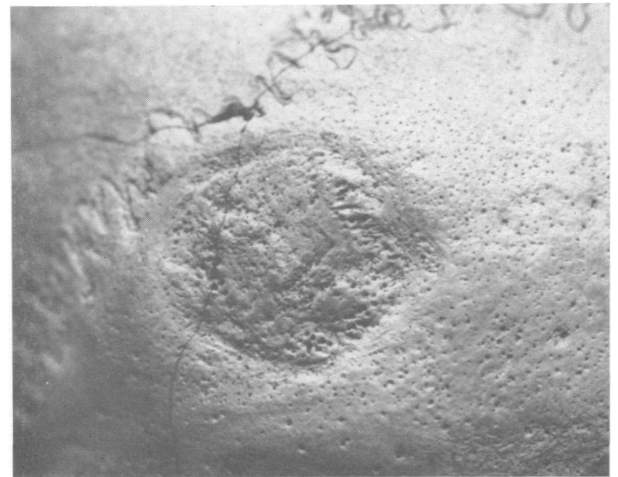
1. Metopic suture, a non-pathological abnormality, usually unites by two years of age. The right side of the orbital margin shows multiple foramina, through which blood vessels and nerves emerge. Damage above left orbit is post-mortem



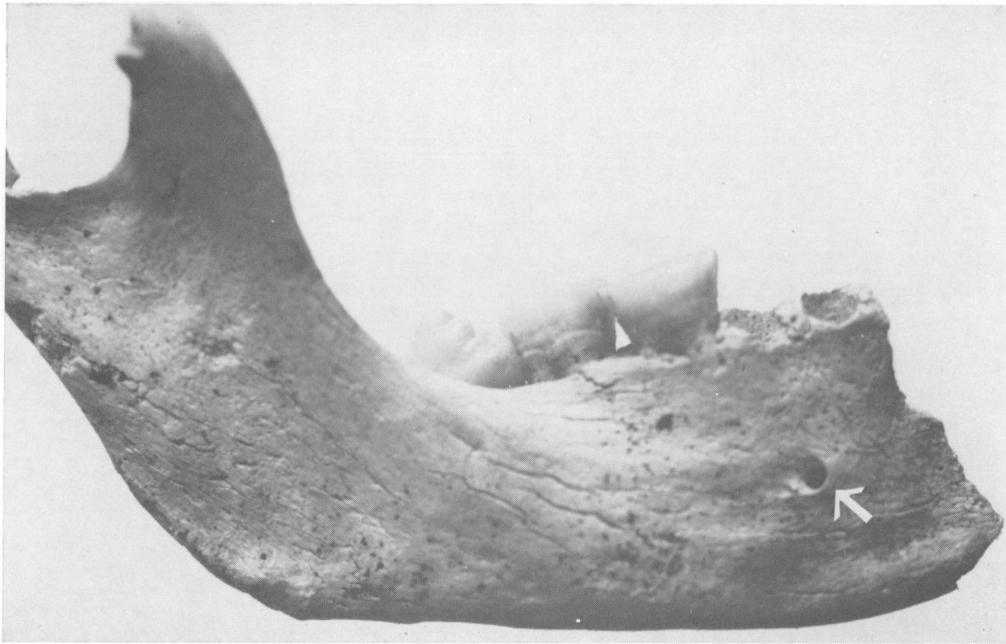2. Right supraorbital foramen and left supraorbital notch, a variation of symmetrical notches, foramina, or multiple foramina—most probably an hereditary pattern



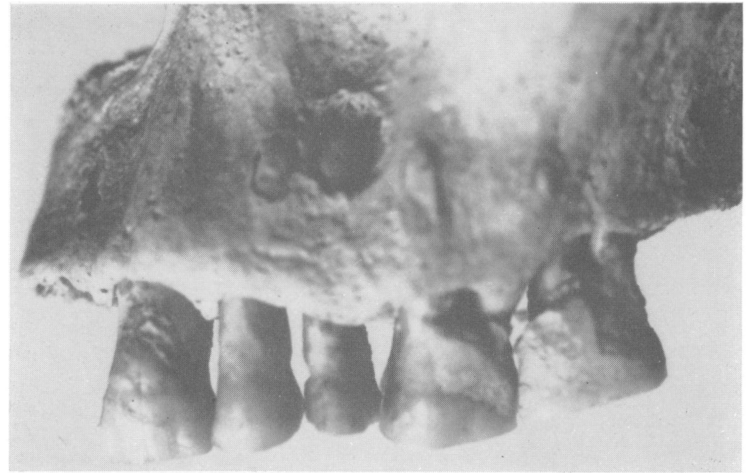3. Bilateral parietal thinning. The fractured bones are due to post-mortem damage



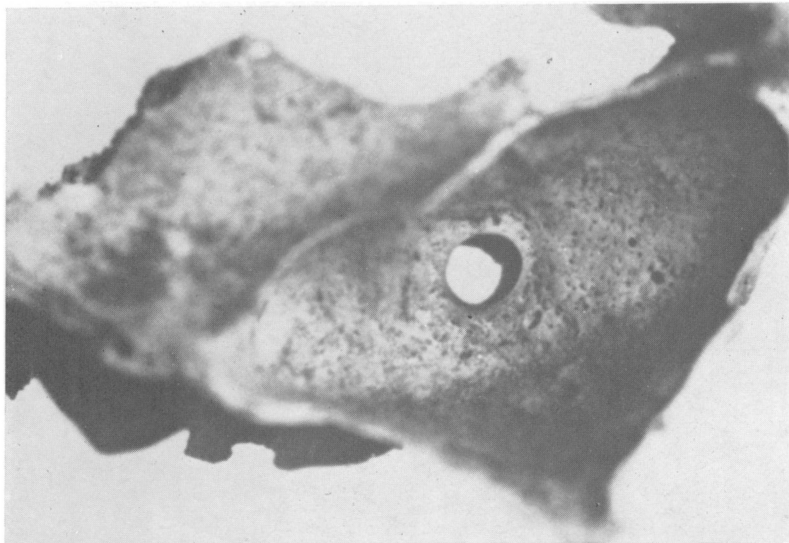
4. Osteoporosis of the parietal bone. The multiple foramina suggest that it is of inflammatory origin



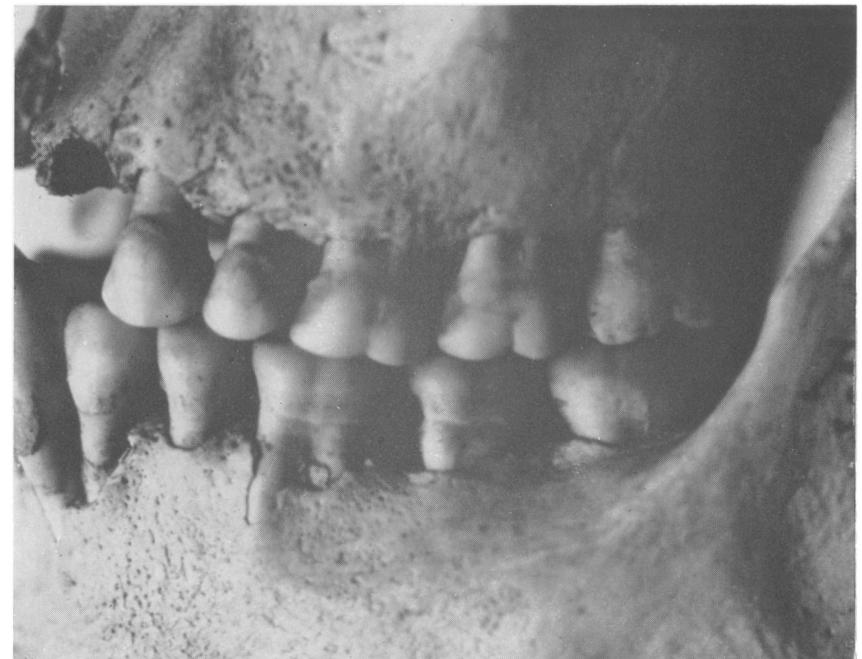1. Mesially impacted lower wisdom tooth. Foramen, marked by arrow, is the mandibular foramen through which emerge blood vessels and nerves



2. Salivary calculus (tartar) is seen on the canine and two molar teeth. Destruction of the alveolar bone above the two premolar teeth is due to necrosis of the dental pulp, the result of exposure of the pulp-chamber by attrition. Roots of the two molar teeth are seen emerging through the alveolar plate, a state resulting from abnormal stresses due to the altered cuspal design caused by attrition



3. Convoluted base of maxillary antrum. The very clean-cut orifice is the result of an apical abscess of a molar tooth making its escape. The more usual pathway is through the outer alveolar plate



4. Perfect alignment and articulation of the buccal teeth, a characteristic of most of the dentitions of this collection. Mesial carious cavity is seen in the lower second molar. Evidence of the commencement of alveolar bone disease